

HeberFERON, formulation based on IFNs alpha2b and gamma for the treatment of non-melanoma skin cancer

Lorenzo Anasagasti-Angulo¹, Yanelda Garcia-Vega², Sonia Collazo³, Yanisel Jimenez-Barban⁴, Edgar Tijerino-Arrieta¹, Yoddali Ballester-Caballero⁵, Vladimir Sánchez-Linares⁶, Jorge Marin-Guerra⁶, Katherine Batista⁷, Yaquelin Duncan-Roberts⁸, Carmen Valenzuela-Silva², Angela Tuero-Iglesias⁸, Leovaldo Álvarez-Falcon⁸, and Iraldo Bello-Rivero⁸

1. Department of Medical Oncology, National Institute of Oncology and Radiobiology, Havana, Cuba

2. Center of Molecular Immunology, Havana, Cuba

3. “Hermanos Ameijeiras” Hospital, Havana, Cuba

4. Ophthalmology Center, “Enrique Cabrera” Hospital, Havana, Cuba

5. “Amalia Simoni” Hospital, Camagüey, Cuba

6. Policlinics Centro and Cabaiguan, Sancti Spíritus, Cuba

7. Polyclinic Mario Gutierrez Ardaya, Holguín, Cuba

8. Department of Clinical Research, Center for Genetic Engineering and Biotechnology, Havana, Cuba

BRIEF REPORT

Please cite this paper as: Anasagasti-Angulo L, Garcia-Vega Y, Collazo S, Jimenez-Barban Y, Tijerino-Arrieta E, Ballester-Caballero Y, Sánchez-Linares V, Marin-Guerra J, Batista K, Duncan-Roberts Y, Valenzuela-Silva C, Tuero-Iglesias A, Álvarez-Falcon L, Bello-Rivero I. HeberFERON, formulation based on IFNs alpha2b and gamma for the treatment of non-melanoma skin cancer. AMJ 2017;10(6):509–515. <https://doi.org/10.21767/AMJ.2017.3013>

Corresponding Author:

Iraldo Bello Rivero

Center for Genetic Engineering and Biotechnology

Ave 31. Cubanacán, Havana. Cuba

Email: iraldo.bello@cigb.edu.cu

ABSTRACT

Background

Surgery remains the procedure of election for the treatment of non-melanoma skin cancer (NMSC). However, after recurrence, or under surgical complex scenarios, other therapeutic modalities have to be indicated. Immune suppression is associated to NMSC; thus, immunotherapy is a rational approach to treat the high spread form of skin tumour.

Aims

We propose a summary of the most relevant clinical results with the combination of IFNs alpha2b and gamma in the treatment of non-melanoma skin cancer.

Methods

In several clinical trials (Open prospective trial; phase 2 double-blind randomized studies: InCarbacel-II and InCarbacel-III; retrospective study and ongoing phase IV trial, InCarbacel-IV) more than 200 patients with histological diagnostic of non-melanoma skin cancer were recruited to be treated with the combination of IFNs in Cuban health institutions at primary, secondary or tertiary care levels. All the studies were approved by institutional ethic committees and all the patients given their written informed consent. HeberFERON was administered, peri- or intralesionally, three times per week, during 3 weeks. Clinical and histological responses were evaluated by RECIST (1.0), three months after the end of treatment.

Results

HeberFERON promoted more rapid and higher number of CRs than separated IFNs (InCarbacel-II study). The open-label prospective study showed 46.7 per cent CR in locally advanced BCC after application of HeberFERON. Patients with periocular BCC or SCSC received benefits from HeberFERON treatment (71.4 per cent OR). Overall, HeberFERON has been administered to patients with non-melanoma skin cancer obtaining a 65 per cent of histological CR together with an excellent safety profile.

Conclusion

HeberFERON is a novel, non-surgical, effective and safe option to treat advanced, high risk or recurrent non-melanoma skin cancer.

Key Words

Interferons, non-melanoma skin cancer, non-surgical

Implications for practice:

1. What is known about this subject?

Some patients with non-melanoma skin cancer are difficult to treat effectively. Advanced, high risk or recurrent lesions, produces high morbidity and in some cases death.

2. What new information is offered in this report?

HeberFERON has been successful as a new therapeutic options for patients with difficult to treat NMSC.

3. What are the implications for research, policy, or practice?

HeberFERON should be recommended for those patients with advanced BCC combined or not with other therapies. It is highly recommended to avoid surgical mutilations as therapeutic indication.

Background

Non-melanoma skin cancer (NMSC) is the most common form of skin cancer. The predominant cause of NMSC is largely associated to exposure to ultraviolet (UV) radiation,¹ likely because of immune suppression.^{2,3} Mutations in tumour suppressor genes, angiogenesis, dysregulation of the Hedgehog (Hh) signalling pathway and evasion of immune system response contribute to developing and perpetuation of NMSC.^{4,5} However, contrary to basal cell carcinoma (BCC), scarce link to genetic variations have been attributed to squamous cell skin carcinomas (SCSC) risk.⁶ Human papilloma viruses (HPV) infections could function as co-factor with UV-radiation for skin cancer risk.⁷

Malignant BCC cells arise from hair follicles, grow slowly and invade locally.⁸ Recurrence of BCC is approximately 12 per cent with the most habitual therapies. Between 40 per cent–50 per cent of patients with a primary lesion will develop at least one further BCC within 5 years.⁹ The rate of recurrence is highly correlated with tumour size and facial location. Approximately 90 per cent of recurrent BCC are related to head and neck. Aggressive histological BCC subtypes recurred more frequently.¹⁰ SCSC can growth from sites with actinic keratosis, chronic wounds or scarring, in the epithelial keratinocytes.¹¹ With respect to BCC, SCSC has

a higher risk of recurrence (8 per cent–15 per cent) and metastasis (0.5 per cent–16.0 per cent).¹²

One per cent–10 per cent of BCCs is difficult to treat, or is more aggressive, or produces multiple recurrences with difficulty for further local surgery or radiotherapy, or requires substantial surgical excision with sometimes complex reconstruction. This characterizes the subset of BCC, called locally advanced basal cell carcinoma (laBCC).¹³

Surgical excision remains the gold standard of treatment for BCC. When used excision with 3–4 mm margins, the results are excellent.¹⁴ However, when eyelid margin is involved, the risk for defect is high even with these surgical wide margins, and the application of reconstructive surgery is needed. In some cases significant amount of normal tissue is compromised.¹⁵

High-risk SCSC¹⁶ is associated with tumour (location, characteristics) and host factors (immunosuppression, chronic leukaemia). The mainstay of treatment for high-risk SCSC is the complete surgical clearance of the lesion with histological free margins. Radiotherapy is also a treatment option. More recently, UV-associated skin cancers has showed sensibility to anti-PD1-mAb treatment.^{17,18}

It has been reported that IFN- α and IFN- γ are been combined with anti-PD1-mab because the combination favour the antitumor immunity.^{19,20}

Unmet medical need is identified for patients with locally advanced or high-risk NMSC or those with indication of mutilation. The high incidence, morbidity, and mortality of complex-to treat BCC and SCSC are a major challenge for Oncology Specialists who have the responsibility to care these patients.

Immunotherapy could be a prominent non-surgical option for NMSC. High-risk skin lesions could specially being benefited from immunotherapy, as well those patients with indication of mutilation.

Case details

Clinical studies

HeberFERON is a pharmaceutical formulation that contains co-formulated IFN- α 2b and - γ in antiproliferative synergistic proportions to inhibit tumour cell growth.

The clinical results of patients from open prospective trial;²¹ phase 2 double-blind randomized studies: InCarbacel-II and

InCarbacel-III;²² retrospective study²³ and ongoing phase IV trial, InCarbacel-IV) are described.

For evaluation the outcomes were classified as complete response (CR: total disappearance of the tumour), partial response (PR: at least a 30 per cent decrease in the sum of the longest diameter of target lesions) by RECIST,²⁴ objective response (CR+PR), disease control rate (CR+PR + stable diseases) or progression.

The first study that demonstrated the superiority of HeberFERON over IFN- α 2b was conducted in 40 patients with surgical BCC, mean age 67-years-old, 57.9 per cent females. The treatment with HeberFERON (n=19) showed 95 per cent OR vs IFN α -2b with 90 per cent (n=21). Complete responses were 42.1 per cent and 33.3 per cent in the HeberFERON and IFN α -2b groups, respectively. Complete response in the HeberFERON group occurred one month before than IFN α 2b or IFN- γ groups.²²

Other clinical trials in patients with advanced NMSC²¹ and periocular BCC or SCSC²³ have demonstrated the impressive anti-tumour activity of this IFN formulation. The results are summarized in Table 1.

The median sustained response in patients with advanced NMSC, treated with HeberFERON, was 38 months at a 95 per cent confidence interval (22.6–53.4). The mean survival was 42.3 months (95 per cent, 29.4–55.2).²¹ In the case of periocular BCC and SCSC, OR was observed in 71.4 per cent of cases (CR: 47.6 per cent + PR: 23.8 per cent), with a response duration of 22.6 months.²³

Pooled data of patients with BCC from several studies,²¹⁻²³ and data of ongoing phase IV clinical trial in patients with BCC of any subtype, size and localization, using the IFNs combination, were processed. The histological classification is described in the Figure 1.

There was practically 100 per cent correlation between clinical and histological CRs (Table 2).

The Figures 2-5 show several pictures of tumours treated with HeberFERON before and after treatment.

The disease control rate was 98.6 per cent. Only three progressions were observed, two localized in the face and the other in the trunk (Table 3).

Discussion

Surgical excision remains the gold standard for the treatment of NMSC with cure rates as high as 95 per cent. However, difficult to treat NMSC is a condition without effective therapy.

Methyl aminolevulinate photodynamic therapy (MAL-PDT) has demonstrated high cure rates with good cosmetic outcomes for NMSC. However, in the case of invasive SCSC, this approach is not recommended.²⁵

HeberFERON produces approximately a 60 per cent and 48 per cent CRs in surgical BCC (recurrent or at diagnostic) and laBCC, respectively. The duration of these responses is maintained for five years (manuscript in preparation) and 38 months²¹, respectively.

Recently two target therapy based on Hh signalling has been approved for the treatment of patients suffering from laBCC.²⁶⁻²⁸ These Hh pathway inhibitors have demonstrated sub-optimal OR rates of 15 per cent to 60 per cent, with median durations of response lower than 12 months.

Apparently, HeberFERON showed higher OR rate (87 per cent, 38 months response duration) than Hh inhibitors for laBCC²¹. Additionally, HeberFERON surpass these target therapies in terms of safety since serious adverse events have not been detected in the evaluated patients.

The phase 1 ERIVANCE study showed that Vismodegib promoted a 60.3 per cent OR in laBCC after 24 months follow-up, 15.5 percent of patients had progressions, and 71.2 per cent developed muscle spasms as most frequent adverse event (AE).²⁶ In a phase 2 trial Sonidegib induced OR in 58.0 per cent of patients with laBCC. Between 3.0 per cent–4.0 per cent of patients had grade-3 AEs (fatigue, muscle spasms, decreased weight).²⁹

Interferons have been shown effectivity in the treatment of BCC and SCCS.^{30,31} Preliminary data from Genomic Laboratory at The Centre for Genetic Engineering and Biotechnology (CIGB), Havana, showed that HeberFERON is likely active on tumour cells by promoting apoptosis and favouring tumour suppressor functions via STAT-1.³²

As suggested before²¹ the apoptosis of BCC cells mediated by CD95 ligand could be potentiated by the type I and type II interferons combination. The potentiation of HeberFERON-induced biological effects has been confirmed in pharmacodynamics studies.^{33,34}

There is an important fact that is need to remark. The evaluation of final clinical and histological response to HeberFERON is measured 13 weeks after the end of administration of the product. There are patients that obtained a CR during the treatment period (3 weeks); however, other started to have CR after the end of the treatment.²² This means that antitumor effect is mediated likely both by direct early effects (induction of apoptosis) and long-lasting activation of innate and adaptive immune responses as a result of IFNs' actions (dendritic cells activation, tumour antigen presentation, NK and T-cell cytotoxicity). The innate and adaptive cellular immune response plays a key role in surveillance and eradication of NMSC.^{35,36} The mechanism of antitumor response in NMSC patients treated with HeberFERON requires further study.

HeberFERON combined with radiotherapy, chemotherapy, target therapies or immune check point inhibitors is a transcendental field of clinical research to be explored and hopefully will increase the benefits of these patients.

Conclusion

HeberFERON impact positively on the lives of advanced, high risk or recurrent NMSC patients; and it is an appropriated therapeutic option for patients suffering from NMSC, difficult to treat or at risk of surgical aesthetic complications or recurrent disease.

HeberFERON is part of both the innate and adaptive immunological response. It plays a key role in immuno-surveillance and may offer patients an amenable approach for preventing and treatment of NMSC.

References

1. Rubin AI, Chen EH, Ratner D. Basal-cell carcinoma. *N Engl J Med.* 2005;353:2262-2269. doi: 10.1056/NEJMr044151.
2. Gaspari AA, Sauder DN. Immunotherapy of basal cell carcinoma: evolving approaches. *Dermatol Surg.* 2003;29:1027-1034.
3. Tessari G, Girolomoni G. Nonmelanoma skin cancer in solid organ transplant recipients: update on epidemiology, risk factors, and management. *Dermatol Surg.* 2012;38:1622-1630. doi: 10.1111/j.1524-4725.2012.02520.x.
4. Hutchin ME, Kariapper MS, Grachtchouk M, et al. Sustained Hedgehog signaling is required for basal cell carcinoma proliferation and survival: conditional skin tumorigenesis recapitulates the hair growth cycle. *Genes Dev.* 2005;19:214-223. doi: 10.1101/gad.1258705.
5. Decicco-Skinner KL, Trovato EL, Simmons JK, et al. Loss of tumor progression locus 2 (tp12) enhances tumorigenesis and inflammation in two-stage skin carcinogenesis. *Oncogene.* 2011;30:389-397. doi: 10.1038/onc.2010.447.
6. Chahal HS, Lin Y, Ransohoff KJ, et al. Genome-wide association study identifies novel susceptibility loci for cutaneous squamous cell carcinoma. *Nat Commun.* 2016;7:12048. doi: 10.1038/ncomms12048.
7. Akgul B, Cooke JC, Storey A. HPV-associated skin disease. *J Pathol.* 2006;208:165-175. doi:10.1002/path.1893.
8. Telfer NR, Colver GB, Morton CA. Guidelines for the management of basal cell carcinoma Guidelines for the management of basal cell carcinoma, British Association of Dermatologists. 2008. doi: 10.1111/j.1365-2133.2008.08666.x.
9. Madan V, Lear JT, Szeimies RM. Non-melanoma skin cancer. *Lancet.* 2010;375:673-685. doi: 10.1016/S0140-6736(09)61196-X.
10. Bath-Hextall FJ, Perkins W, Bong J, et al. Interventions for basal cell carcinoma of the skin. *Cochrane Database Syst Rev.* 2007;24:CD003412.
11. Wusheng Y, Ignacio IW, Michael EB, et al. Squamous cell carcinoma – similarities and differences among anatomical sites. *Am J Cancer Res.* 2011;1:275-300.
12. Tobin JS, Jimmy JC, Louis BH. Management of BCC and SCC of the Head and Neck. *Cancer Control.* 2016;23:220-227.
13. Shalini VM, Chang AL. Advanced Basal Cell Carcinoma: Epidemiology and Therapeutic Innovations. *Curr Derm Rep.* 2014;3:40-45. doi: 10.1007/s13671-014-0069-y.
14. Doxanas MT, Green WR. Factors in the successful surgical management of basal cell carcinoma for the eyelid. *Am J Ophthalmol.* 1981;91:726-736.
15. Anderson RL. Comment on Glatt HJ, Olsen JJ, Putterman AM, Conventional frozen sections in periocular basal-cell carcinoma: a review of 236 cases. *Ophthalmic Surg.* 1992;23:6-9.
16. Jennings L, Schmults CD. Management of High-Risk. Cutaneous Squamous Cell Carcinoma. *J Clin Aesthetic Dermatol.* 2010;3:39-48.
17. Falchook GS, Leidner R, Stankevich E, et al. Responses of metastatic basal cell and cutaneous squamous cell carcinomas to anti-PD1 monoclonal antibody REGN2810. *J Immunother Cancer.* 2016;4:70. doi: 10.1186/s40425-016-0176-3.
18. Lipson EJ, Lilo MT, Ogurtsova A, et al. Basal cell carcinoma: PD-L1/PD-1 checkpoint expression and tumor regression after PD-1 blockade. *J Immunother Cancer.* 2017;5:2. doi: 10.1186/s40425-017-0228-3.

19. Peng W, Liu C, Xu C, et al. PD-1 blockade enhances T-cell migration to tumors by elevating IFN-gamma inducible chemokines. *Cancer Res.* 2012;72:5209-5218. doi: 10.1158/0008-5472.CAN-12-1187
20. Lee J, Ahn E, Kissick HT, et al. Reinvigorating Exhausted T Cells by Blockade of the PD-1 Pathway. *For Immunopathol Dis Therap.* 2015;6:7-17. doi:10.1615/ForumImmunDisTher.2015014188.
21. Anasagasti-Angulo L, Garcia-Vega Y, Barcelona-Perez S, et al. Treatment of advanced, recurrent, resistant to previous treatments basal and squamous cell skin carcinomas with a synergistic formulation of interferons. Open, prospective study. *BMC Cancer.* 2009;9:262-274. doi: 10.1186/1471-2407-9-262.
22. Bello-Rivero I, Garcia-Vega Y, Valenzuela-Silva C, et al. Development of a new formulation of interferons (HEBERPAG) for BCC treatment. *Cancer Res Ther.* 2013;10:235-243. doi: <http://dx.doi.org/10.14312/2052-4994.2013-36>.
23. Yanelda G, Lorenzo A, Carmen V. Retrospective Study of Periocular Non Melanoma Skin Cancer Treated with the Combination of IFN alpha2b and Gamma (HeberPAG). *J Clin Exp Ophthalmol.* 2015;6:478. doi:10.4172/2155-9570.1000478.
24. Therasse P, Arbuck SG, Eisenhauer EA, et al. New Guidelines to Evaluate the Response to Treatment in Solid Tumors. *J Natl Cancer Inst.* 2000;92:205-216.
25. Stebbins WG, Hanke CW. MAL-PDT for difficult to treat nonmelanoma skin cancer. *Dermatol Ther.* 2011;24:82-93. doi: 10.1111/j.1529-8019.2010.01381.x.
26. Sekulic A, Migden MR, Oro AE, et al. Efficacy and Safety of Vismodegib in Advanced Basal-Cell Carcinoma *N Engl J Med.* 2012;366:2171-2179. doi: 10.1056/NEJMoa1113713.
27. Migden MR, Guminski A, Gutzmer R. Treatment with two different doses of sonidegib in patients with locally advanced or metastatic basal cell carcinoma (BOLT): a multicenter, randomised, double-blind phase 2 trial. *Lancet Oncol.* 2015;16:716-728. doi: 10.1016/S1470-2045(15)70100-2.
28. Mohd W, Arshad J, Sajad AD, et al. Differential pharmacology and clinical utility of sonidegib in advanced basal cell carcinoma. *Onco Targets Ther.* 2017;241:515-520. doi: 10.2147/OTT.S97713.
29. Migden MR, Guminski A, Gutzmer R. Treatment with two different doses of sonidegib in patients with locally advanced or metastatic basal cell carcinoma (BOLT): a multicenter, randomised, double-blind phase 2 trial. *Lancet Oncol.* 2015;16(6):716-728. doi: 10.1016/S1470-2045(15)70100-2.
30. Ikić D, Padovan I, Pipić N, et al. Interferon reduces recurrences of basal cell and squamous cell cancers. *Int J Dermatol.* 1995;34:58-60.
31. Chimenti S, Cotellessa C, Peris K, et al. Use of recombinant interferon alpha-2a in the treatment of squamous cell carcinoma. *J Dermatolog Treat.* 1995;6:163-166. doi: 10.3109/09546639509097175.
32. Bello-Álvarez C, Vázquez-Blomquist D, Miranda J, et al. Regulation by IFN- α /IFN- γ coformulation (HeberPAG) of genes involved in Interferon-STAT pathways and Apoptosis in U87MG. *Curr Top Med Chem.* 2014;14:351-358.
33. García-Vega Y, García-García I, Collazo-Caballero SE, et al. Pharmacokinetic and pharmacodynamic characterization of a new formulation containing synergistic proportions of interferons alpha-2b and gamma (HeberPAG(R)) in patients with mycosis fungoides: an open-label trial. *BMC Pharmacol Toxicol.* 2012;13:20. doi: 10.1186/2050-6511-13-20.
34. García-García I, Hernández-González I, Díaz-Machado A, et al. Pharmacokinetic and pharmacodynamic characterization of a novel formulation containing co-formulated interferons alpha-2b and gamma in healthy male volunteers. *BMC Pharmacology and Toxicology.* 2016;17:58. doi: 10.1186/s40360-016-0103-8.
35. Euvrard S, Kanitakis J, Claudy A. Skin cancers after organ transplantation. *New Engl J Med.* 2003;348:1681-91. doi: 10.1056/NEJMra022137.
36. Walter A, Barysch MJ, Behnke S, et al. Cancer-testis antigens and immunosurveillance in human cutaneous squamous cell and basal cell carcinoma. *Clin Canc Res.* 2010;16:3562-70. doi: 10.1158/1078-0432.CCR-09-3136.

ACKNOWLEDGEMENTS

The authors wish to thank technicians Ketty Cruz, Grettel Melo, Ivan Campa MSc and Dr Cimara Bermudez from CIGB for their assistance in pharmaceutical product preservation and distribution, Idrian Garcia PhD, from CIDEM, for review and corrections of the manuscript. The authors received free HeberFERON from Heber Biotec, Havana, Cuba. The Ministry of Public Health of Cuba supported the clinical trials (medical care of the patients, diagnostic procedures, laboratory test and the other medications).

PEER REVIEW

Not commissioned. Externally peer reviewed.

CONFLICTS OF INTEREST

Authors YDR, ATI, and IBR, are employees of the Center for Genetic Engineering and Biotechnology, Havana network,

where HeberFERON is produced. The other authors have no competing interests.

FUNDING

None

ETHICS COMMITTEE APPROVAL

All the trials were approved by the corresponding Institutional Ethics Committees.

Figure 1: Histological classification of BCC in those patients treated with HeberFERON

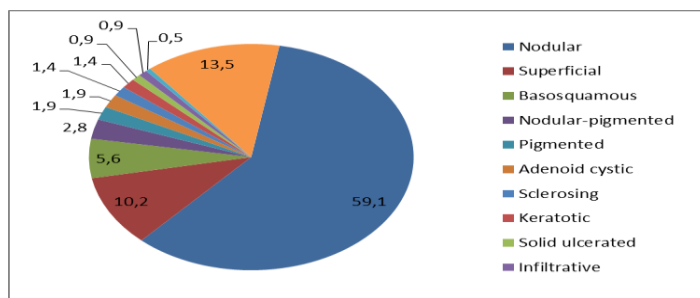


Figure 2: Male patient 48 year-old before treatment (A). Tumour was treated with 10.5 MIU, 2 times a week for 5 weeks at Policlinic Centro, Santi Spiritus. The treatment was temporally interrupted (during the third week) for one week, due to local erythema and inflammation. After the interruption the patient continued the treatment to complete de 9 injections. CR response was observed at 16 weeks (B)

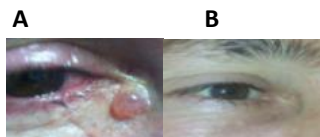


Figure 3: Nodule ulcerative basal cell carcinoma. Male patient 68 years-old before treatment (A). Tumour was treated with HeberFERON at Policlinic Cabaiguan, Santi Spiritus, with 10.5 MIU 3 time a week for 3 weeks. CR response at 18 weeks (B)

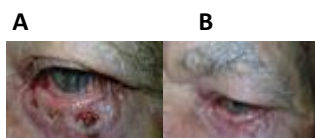


Figure 4: Nodule ulcerative BCC. Female patient 80 year-old before treatment (A), treated with HeberFERON 3.5 MIU 3 time a week for 3 weeks with CR at 16 weeks (B) by dermatoscopy and histology

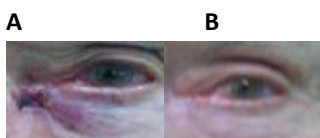

Figure 5: Locally infiltrating advanced BCC with destruction of both eyelids in left eye (A). Patient treated with intralesional HeberFERON concomitant with Cisplatin with CR. Follow-up of 10 year outcome (B)

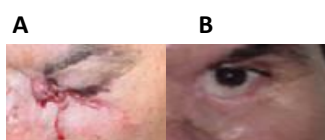


Table 1: A summary of the two clinical trials in patients with advanced NMSC treated with HeberFERON

Cohort	Patients	Response rate	Median duration of response	Serious adverse events
Locally advanced BCC and SCC. Anasagasti-Angulo et al. ²¹	16	87.0%	38.0 months	0%
Periocular BCC and SCC. Garcia-Vega et al. ²³	21	71.4%	22.6 months	0%

Table 2: Clinical and histological responses BCC subtypes from 215 patients evaluated

Histological subtypes	Clinical response				Total	Histological response
	Complete response	Objective response	Disease control rate	Progression		
Nodular	77 (60.6)	108 (85.0)	125 (98.4)	2 (1.6)	127 (59.1)	52 (68.4)
Superficial	18 (81.8)	21 (95.5)	22 (100.0)	0 (0.0)	22 (10.2)	14 (87.5)
Basosquamous	10 (83.3)	11 (91.7)	11 (91.7)	1 (8.3)	12 (5.6)	7 (77.8)
Nodular-Pigmented	3 (50.0)	5 (83.3)	6 (100.0)	0 (0.0)	6 (2.8)	2 (100.0)
Pigmented	0 (0.0)	3 (75.0)	4 (100.0)	0 (0.0)	4 (1.9)	1 (33.3)
Adenoid-cystic	3 (75.0)	4 (100.0)	4 (100.0)	0 (0.0)	4 (1.9)	2 (50.0)
Sclerosing	3 (100.0)	3 (100.0)	3 (100.0)	0 (0.0)	3 (1.4)	2 (100.0)
Keratotic	2 (66.7)	3 (100.0)	3 (100.0)	0 (0.0)	3 (1.4)	1 (50.0)
Solid ulcerated	0 (0.0)	1 (50.0)	2 (100.0)	0 (0.0)	2 (0.9)	0 (0.0)
Infiltrative	2 (100.0)	2 (100.0)	2 (100.0)	0 (0.0)	2 (0.9)	2 (100.0)
Pleomorphic	0 (0.0)	1 (100.0)	1 (100.0)	0 (0.0)	1 (0.5)	--
Without classification	15 (51.7)	28 (96.6)	29 (100.0)	0 (0.0)	29 (13.5)	12 (54.5)
Total	133 (61.9)	190 (88.4)	212 (98.6)	3 (1.4)	215 (100.0)	95 (67.9)

Table 3: Clinical and histological responses of histological BCC subtypes from 215 patients evaluated according to tumour localization.

Tumour Localization	Clinical response				Total	Histological response
	Complete response	Objective response	Disease control rate	Progression		
Face	57 (55.3)	90 (87.4)	101 (98.1)	2 (1.9)	103 (47.9)	38 (63.3)
Trunk	21 (61.8)	27 (79.4)	33 (97.1)	1 (2.9)	34 (15.8)	19 (76.0)
Nose	20 (71.4)	26 (92.9)	28 (100.0)	0 (0.0)	28 (13.0)	13 (65.0)
Arms	14 (70.0)	18 (90.0)	20 (100.0)	0 (0.0)	20 (9.3)	8 (66.7)
Eyelids	7 (77.8)	9 (100.0)	9 (100.0)	0 (0.0)	9 (4.2)	5 (83.3)
Auricular pavilion	7 (87.5)	7 (87.5)	8 (100.0)	0 (0.0)	8 (3.7)	5 (71.4)
Neck	5 (71.4)	7 (100.0)	7 (100.0)	0 (0.0)	7 (3.3)	6 (100.0)
Scalp	2 (33.3)	6 (100.0)	6 (100.0)	0 (0.0)	6 (2.8)	1 (25.0)
Total	133 (61.9)	190 (88.4)	212 (98.6)	3 (1.4)	215 (100.0)	95 (67.9)