

MRI rat organ Assessment under recurrent Interferon administration

Carlos Cabal¹, Evelio González¹, Dania Bacardí¹, Iraldo Bello¹, Juan Carlos Romero¹, Roberto Madrigal¹, Osmany Mendoza¹, Armando Olivera Martínez²

¹Center for Genetic Engineering and Biotechnology (CIGB)

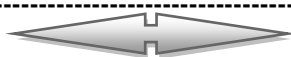²Medical-Surgical-Research Center (CIMEQ)

ABSTRACT

This study aims to assess serial and transverse quantitative Magnetic Resonance Imaging (MRI) in four rat groups using different doses of a formulation based on the combinations of IFN alpha 2b and gamma. Axial and coronal T1, T2 and Diffusion MRI images have been performed in order to follow up morphological and tissue texture changes in the rat brain, cerebellum, spinal cord and kidney. As a result, no morphological changes have been observed during 28 days in any of the four groups including the placebo. Yet, doses until 15 times were bigger than the therapeutic dose. This MRI studies is robust and complementary evidence that the pharmaceutical formulation mixing in the same vial IFNs alpha2b and gamma is safe. For the first time, results of a longitudinal MRI study in rats based on the effects of this pharmacological combination are reported.

Interferon: toxicology, Magnetic Resonance Imaging, rats, doses

Date of Submission: 01 April 2016



Date of Accepted: 10 May 2016

I. Introduction

The combination of IFNs for the treatment of cancer has been experimented since the first years of the discovery of IFNs [1]. However, nor rationally design of combinations aborted many efforts to exploit the truly biological potency of these cytokines. A rationale design of the combination of both molecules based on their anti-proliferative synergism on several tumor cell lines, identified which proportion are more adequate to be combined to obtain the best clinical results [1]. To achieve this, first in class, a pharmaceutical formulation of mixed in the same vial IFNs alpha2b and gamma in anti-proliferative synergistic proportion was developed.

The synergy of this compound, preclude a more potent biological activity and as a consequence could be expected to be more toxic in some issues. A major factor contributing to the attrition during the development of new biotechnology products is a result of positive toxicology findings that cannot be managed with current assays.

Magnetic Resonance Imaging (MRI) methods are playing a rising significant role in toxicological studies by complementing and accelerating these assays, increasing the speed and reliability of the results. The shortened experimental times and reduced labor for histological studies, smaller requirements concerning the number of experimental animals and decreased costs together with higher accuracy and precision for the structural and functional information are afforded by MR require a special attention focused on these emergent

methods. [2-9]. Occurrence of potentially harmful structural and functional tissue alterations can be monitored longitudinal. Such studies should be of great value to pharmacological research and will ultimately show whether imaging techniques might be used, as complement, in a broader sense for evaluation of drug safety. Otherwise it is well established that clinical machine can be successfully used to the rodent's studies [10-15].

The current work presents the MRI results in a serial and transverse quantitative study of four rat groups with different doses of this new formulation (based on the combinations of IFN alpha 2b and gamma) in order to follow up any morphological and tissue texture change in the rat brain, the cerebellum, spinal cord and kidney. For the first time, results of a longitudinal MRI study in rats based on the effects of IFN alpha and gamma 2b combinations are presented.

II. Materials and methods

The study was carried out following the ethical norms described for the use of the laboratory animals [16]; the Guides of Laboratory Good Practices [17, 18] and the Standard Operation Procedures [19].

Test system

Adult albino rats, strain Cenp: Sprague Dawley, of both sexes, 6-8 weeks old, were purchased from The National Center for Production of Laboratory Animals, CENPALAB [18,20,21]. Rats were maintained under standard laboratory conditions. They were clinically examined, registered by body weight and allocated in Makrolón boxes with wood sterile bed. They stayed in observation during 7 days, complying with the acclimation period and then separated for dosing and food consumption measurement using a random list generated by the software Randomization Program Animals Over Cages, R.F. Marsman Bilthoven, RIVM, The Netherlands (version 94–1). They were fed with EMO-1002 diet (ALYco, CENPALAB) 25 grams per animal daily, and water *ad libitum*.

The study was carried out with 10 rats of both sexes (5 females and 5 males), 6-8 weeks old with an average body weight between 216.2 gr (females) and 263.8 gr (males). The variation of weight didn't exceed $\pm 20\%$ for both sexes.

Before providing the product, all animals were studied by MRI in order to have a T0 reference and for quality control.

Experimental design

Table I. Doses and treatment per groups.

Group	Number/Sex	Treatment	CIGB-128-A (MUI)	
			♀	♂
I	1 ♀, 1 ♂	Placebo	0	0
II	1 ♀, 1 ♂	CIGB-128-A (3 times up Therapeutic dose)	0.09	0.13
III	1 ♀, 1 ♂	CIGB-128-A (7 times up Therapeutic dose)	0.12	0.29
IV	2 ♀, 2 ♂	CIGB-128-A (15 times up Therapeutic dose)	0.28	0.58

The animals were treated once daily on alternate days to complete 9 injections by intravenous route. These four groups have been examined by MRI before the first administration after each inoculation during 28 days. The used anesthetic was a mixture of 100 mg of ketamine, 2.5 mg of midazolam and 0.1 mg of atropine injected by intraperitoneal route.

Positioning and fixing the rats.

Immediately after the anesthesia, two rats were placed and immobilized in a designed device, a prone position, enclosed in the Flex-S RF coil in order to guarantee the reproducibility of the rats positioning during each test and between different exams (Figure 1). Finally, the rats were placed to the center of the MRI magnetic system.

Magnetic resonance sequences

MRI examination was performed with a 1,5 T Symphony Master Class system (Siemens, Germany). The sequences used were T1 Spin Echo (coronal, axial and sagittal) with Echo Time (TE) and Repetition Time (TR) 12 ms and 478 ms, respectively. The axial and coronal T2 Turbo Spin Echo images (TSE) were performed with TR = 4000 ms, TE = 96 ms. In all cases, the slice thickness was 2 mm and the inter slices gap was zero mm. A specially designed device as used to ensure reproducibility of fixation and position of rats [22] (Figure 1). The pulse sequences were calibrated to use a clinical MRI machine to obtain image of small animal model with diagnostic value and spatial resolution of 150um [22].

The Diffusion Weighted Images (DWI) were registered by Single Shot Echo Planar Imaging (SSEPI) sequence for three *b* values (0, 500, and 1000 s/mm²) in x, y and z directions, TE= 80 ms; TR= 3000 ms, slice thickness 2,2 mm and, inter slice gap 0 mm. The ADC values were calculated from images obtained by DWI and using Matlab. 7. x software.




Image storage and processing

MRI data were stored and processed in DICOM format in a database using eFilm 2.x. The areas and volumes calculations were performed manually using Amira 5.1.0 and Matlab. 7.x. The existence of statistically significant differences between the values obtained for each volunteer and patient was examined with an ANOVA-test for normally distributed data of homogeneous variance. Statistical significance was set at $p < 0.05$. The statistical analysis was also implemented using

The Development criteria for measuring the geometrical dimensions of the brain, cerebellum (Fig 2) are described below.

A) For brain measurement, a coronal section was selected in which the olfactory bulb, the brain and the fourth ventricles were observed. In this section, the major axis of the brain (MaB) was measured as the distance from the end of the olfactory bulb through midline to the 4th ventricle (Figure 2A). The minor axis of the brain (MiB) was assessed as the distance perpendicular to the first slice was taken passing through the ventricles.

B) For Cerebellar measurement, the axial slices were chosen where the cerebellum and the 4th ventricle are observed. The major axis of the cerebellum (MaC) was selected as a greater length (Figure 2B). The minor axis of the cerebellum (MiC) was carefully chosen as a lower length. It ranges from the 4th ventricle to the outer edge of the cerebellum (Figure 2B).

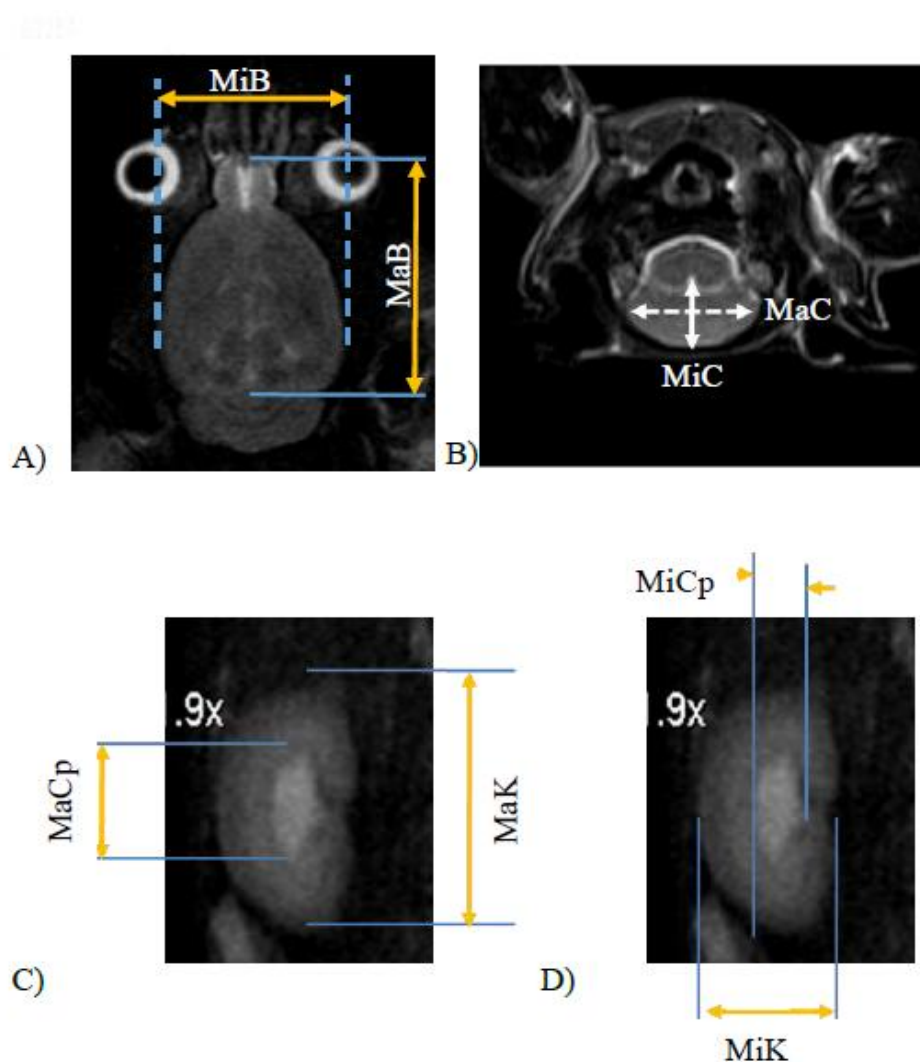


Figure 2. (A) Coronal slice of the brain of a rat where its major axis (MaB) and lower (MiB) are indicated. (B) Axial section of a rat cerebellum in which its major axis (MaC) and lower (MiC) are marked (C and D). Coronal (C) right and (D) left slice kidney of a rat. It shows how the measure lengths of outer capsule and renal pelvis is selected.

In both cases, five measurements were made and the mean and standard deviation were calculated.

Development criteria for measuring the Kidney's geometrical dimensions.

The possible effect of dose in the kidney morphology was also studied. Therefore, measurements were performed to characterize the kidney dimension. It was carried out in both kidneys (left and right) the larger length (MaK) and the lower (MiK) of the renal pelvis. The largest dimensions (MaCP) and the lower (MiCp) of the outer capsule were also obtained (figures 2C and 2D).

The Statistical analysis.

The statistical analysis was conducted at two time points, the initial (T0) and final (T9) time depending on the evaluated groups (I, II, III and IV). They were estimated as descriptive characteristics of the variables to measure central tendency and dispersion (mean, standard deviation and maximum and minimum values). Whether they do not fulfil the normal distribution, the median and interquartile ranges were also estimated. The assumptions of normality (Kolmogorov-Smirnov and Shapiro-Wilk) and homogeneity of variances (Levene test) were verified. Depending on their compliance or not, a Kruskal Wallis test was performed to compare variables. Paired comparisons in time intervals (T1 and T9) were also performed using the Wilcoxon test.

The statistical analysis was also implemented using SPSS 8.0 software for Windows, version 15.

III. Results

In figure 3, MRI T2 coronal slices of the skull from some animals at T0 are shown with a voxel resolution of $0.15 \times 0.15 \times 1.5$ mm where the brain, the cerebellum and the ventricular system are clearly observed.

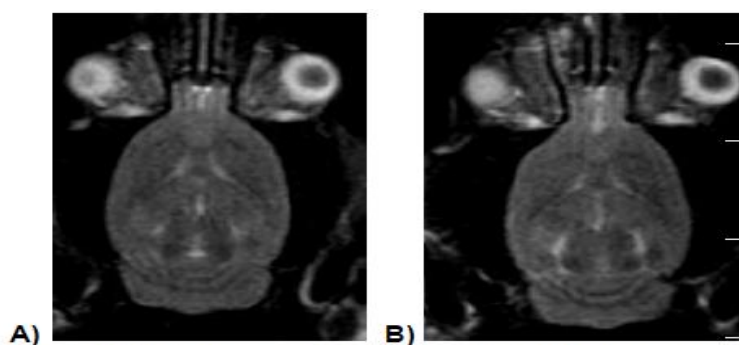


Figure 3. MRI T₂ coronal slices of the skull from the animals II04 (A) and II14 (B), (voxel $0.15 \times 0.15 \times 1.5$ mm) at T0 are shown. The cerebellum, brain and ventricular system healthy is clearly observed.

Pretreatment evaluation of the images showed that rat VII02 finding presented a ventricular dilation (Figure 4A). The monitoring of this injury during the study did not change location, extent or appreciable intensity. Also, in the VII12, hyper intense areas were observed in the right kidney showing the impression as kidney cysts. Its dimensions and locations also underwent changes during the study marked by two rounded in the right kidney in the Figure 4B.

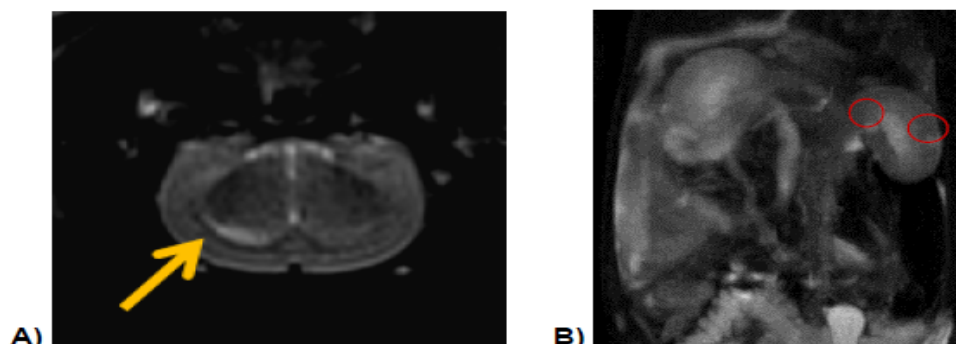


Figure 4. Findings in pre-treatment studies. A) Axial slice of the animal VII 02 wherein the ventricular asymmetry, indicated by the arrow, was observed. B) A coronal slice of the animal VII12, hyper intense images in the left kidney, indicated by circles, was observed.

Figure 5, as an example, shows brain images of the different groups at three dissimilar moments.

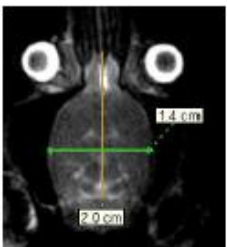
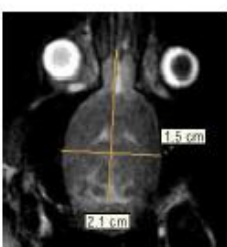
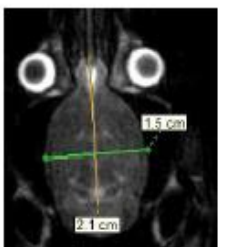
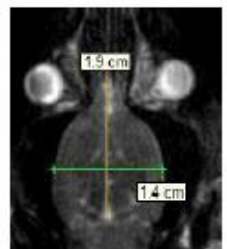
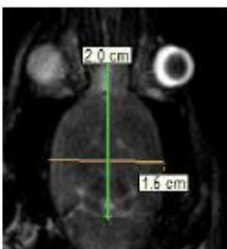
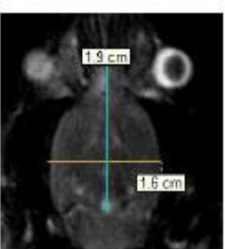
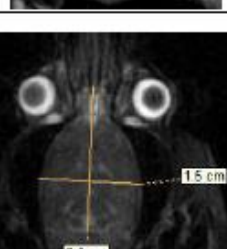
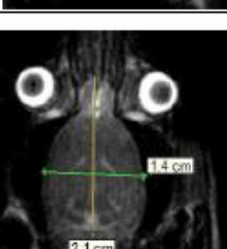
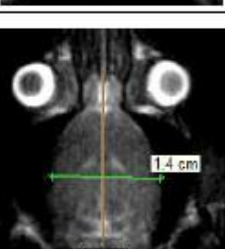
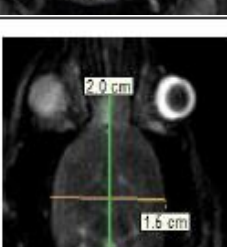
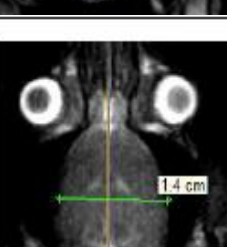
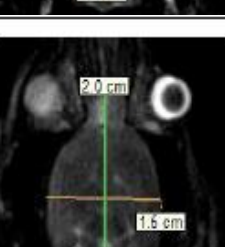
Group, (animal)	T0	T4	T9
II (04)			
III (02)			
IV (05)			
VII (04)			

Figure 5. The MR Images of the rats brain at dissimilar groups under study at three moments. T0 was scanned previously the first administration. T4 and T9 correspond to 4 and 9 weeks of the systematic inoculation respectively. No qualitative differences in the morphology are observed.

The data were not normally distributed. Tables 2.1-2.3 show the results of the Kruskal Wallis for T0 and T9 times evidencing no statistically significant variations between treatments (groups) from the start to the end times.

The comparison between T0 and T9 also showed no significant changes ($p > 0.05$) (table 2.1 and 2.3).

Therefore, we can support that the new drug in the doses studied has no toxic effects on the organs studied ($p > 0.05$) (Table 2.1 -2.2).

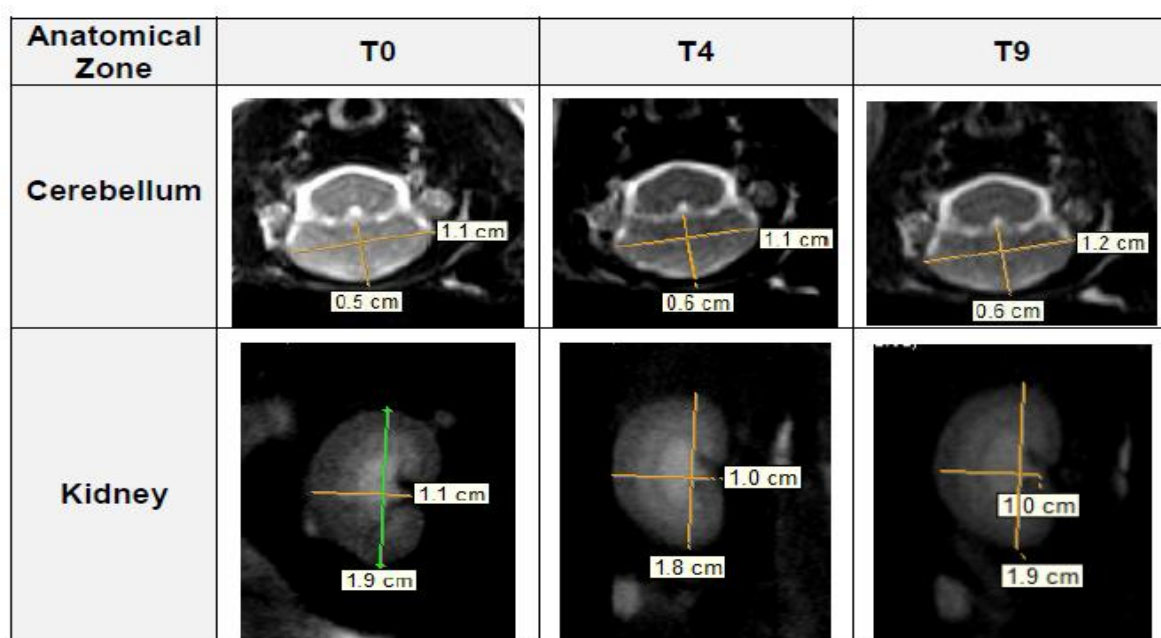


Figure 6. The MR Images of the cerebellum (axial slice) and kidney (coronal slice) of animal VII (04) at three different times. T0 was previously scanned the first administration. T4 and T9 correspond to 4 and 9 weeks of the systematic inoculation respectively. No qualitative or quantitative differences in the morphology are observed.

Additionally, figure 6 shows MRI of the cerebellum and right kidney of rat # VII (04) for different times. With the techniques T2, T1 (in axial and coronal slices) and DWI no alterations in morphology, size and relative position of structures and appearance of lesions in the brain, cerebellum, spinal cord and kidneys were observed with an accuracy of ± 150 microns in any of the five groups studied for 28 days.

Table 2.1 Kruskal Wallis Test for T0 and T9 time. No differences between groups were observed ($p < 0.05$)^{a,b,c}.

Time		MiB	MaB	MiC	MaC	MiK D	MaK D	MiCp D	MaCp D	MiCp I	MaCp I	MiK I	MaK I
T0	χ^2	2.41	2.83	8.14	2.18	1.13	5.28	.60	2.68	3.59	7.23	5.77	7.00
	df	3	3	3	3	3	3	3	3	3	3	3	3
	Asymp Sig	0.49	0.42	0.05	0.54	0.77	0.15	0.90	0.44	0.31	0.07	0.12	0.07
T9	χ^2	3.36	4.76	5.91	4.62	3.00	0.75	7.18	5.46	7.70	7.32	6.52	6.74
	df	3	3	3	3	3	3	3	3	3	3	3	3
	Asymp Sig	0.34	0.19	0.12	0.20	0.39	0.86	0.07	0.14	0.05	0.06	0.09	0.08

a. Kruskal Wallis Test b. Grouping Variable: grupo c. degree freedom (df)

Table 2.2. Kruskal Wallis Test and Wilcoxon Signed Ranks Test. No differences between groups were observed. By comparing the behavior of each variable in time, no statistically significant differences were found^{a,b}.

	Time		MiB	MaB	MiC	MaC	MiK D	MaK D	MiCp D	MaCp D	MiCp I	MaCp I	MiK I	MaK I
Test Wilcoxon	T0	χ^2	3.00	3.00	3.00	3.00	3.00	3.00	3.00	3.00	3.00	3.00	3.00	3.00
		df	3	3	3	3	3	3	3	3	3	3	3	3
		Asymp Sig	0.39	0.39	0.39	0.39	0.39	0.39	0.39	0.39	0.39	0.39	0.39	0.39
	T9	χ^2	3.00	3.00	3.00	3.00	3.00	3.00	3.00	3.00	3.00	3.00	3.00	3.00
		df	3	3	3	3	3	3	3	3	3	3	3	3
		Asymp Sig	0.39	0.39	0.39	0.39	0.39	0.39	0.39	0.39	0.39	0.39	0.39	0.39
Ranks Test	T9-T0	Z	0.00 ^a	-1.46 ^b	.000 ^a	-1.82 ^b	-1.47 ^b	-9.21 ^b	-1.29 ^b	-1.10 ^b	-1.46 ^b	-1.46 ^c	-7.73 ^b	-1.10 ^c
		Asymp. Sig (2-tailed)	1.00	.144	1.00	0.068	0.141	0.357	0.197	0.273	0.144	0.144	0.465	0.273

a. The sum of negative ranks equals the sum of positive ranks. b. Based on negative ranks, c. Based on positive ranks. d. Wilcoxon Signed Ranks Test

Table 2.3. Mean values ADC map obtained in the right and left hemispheres of the brain of rats in times T0 and T9. There were no statistically significant differences (ns) between the hemispheres, or in time.

Time	ADC mean ($\times 10^{-6}$) mm ² /s		
	Left hemisphere	Right hemisphere	
T0	76.4 \pm 4.6	72.1 \pm 4.3	n.s
T9	75.0 \pm 3.5	73.4 \pm 3.8	n.s
	n.s	n.s	

Similarly, the DWI do no present any variation in all of the four groups, placebo and three different dose levels during the 9 weeks of administration (Table 2.3).

IV. Discussion

The good reproducibility of the rat position along the 8 weeks study allowed measuring the possible dimensions changes of the brain, cerebellum, and kidney with a better precision than 150 microns. No morphological changes have been observed during 28 days in none of the four groups studied, while doses until 15 times were bigger than the therapeutic dose. Along this time, no visible lesion in the T1, T2 and DWI images appeared.

Imaging findings in animals before treatment demonstrate the importance of the characterization of the population or at least a sample of them before you start using them. Perhaps this increases costs, but it is a way of ensuring that they do not have silent injuries attributable at the end to the new drugs effects.

As it is well known, DWI is a powerful method where the images somehow reflect the intensity and direction of the water molecules movement in each micro zone of the object under examination. The H₂O diffusion at each voxel depends on bio-structural factors; *e.g.* cell membranes and density and organization such as organelles, macromolecules and tissue micro-architecture. Indeed, ADC values calculated from images provide some evidence related to the tissue texture in each micro region as discussed by Khoo [9]. Consequently, DWI has opened up a wide array of experimental choices, given its increased sensitivity to cell density variations and tissue anomalies as well as the possibility of detecting affected zones at earlier stages than with T1- or T2-weighted imaging. DWI did not present any variation in all of the four groups, the placebo and three different doses levels during the 9 weeks of administration.

This study including T1, T2 and DWI was strong and complementary evidence that the pharmaceutical formulation mixing in the same vial IFNs alpha2b and gamma is safe.

Such imaging results are in agreement with those of the histopathological studies carried after the animals have been sacrificed. During the macroscopic observation of the autopsy, indicative signs of alterations were not detected in the organs and tissues. All the organs showed normal morphology without evidences of anatomical changes. The absence of gross findings in the organs 11 and tissues is an important element when analyzing the safety of the product that was rehearsed in this study.

The histology of all the evaluated organs by treatment group has been similar and independent of the used dose levels. Thus, toxic effects were not observed of the test item on the animals.

Taking into account, there were no previous reports found with similar studies for these cancer therapies; this is the first time, results of a longitudinal MRI study in rats on the effects of combinations of IFN alpha and gamma 2b are reported.

V. Conclusion

On the whole, from T1 and T2 MR Images (coronal and axial slice orientation) no morphological changes were observed in the Brain, cerebellum, Medulla spinal and Kidney during 28 days. Likewise, any kind of lesion during this period has been observed. In fact, the DWI corroborates this result.

Clinical MRI machines and methods provide good complementary information for the toxicological serial and transverse quantitative studies.

In the frame work of this study, the pharmaceutical formulation by MRI mixing in the same vial IFNs alpha2b and gamma is safe and has no toxicity visible effect in a wide dose range. For the first time, results of a longitudinal MRI study in rats on the effects of this pharmacological combination are shown.

Acknowledgments

The authors wish to thank to the CIGB and the Medical-Surgical-Research Center CIMEQ for supporting this work.

References

- [1] Stable formulation containing enhancing proportions of Gamma and Alpha Interferons. WO/2007/051431
- [2] Cabal C, González E, Torne Y, Rojas A. 2009. Imágenes moleculares y micro-imágenes de resonancia magnética en la biotecnología y la farmacéutica modernas. *J. Biotecnología Aplicada*. 26: 293-303.
- [3] Tengowski MW, Kotyk JJ. 2005. Risk identification and management: MRI as a research tool in toxicology studies of new chemical entities: Progress in Drug Research, Rudin M. Birkhäuser Verlag: Basel Switzerland, Vol. 62
- [4] Rodríguez I, Pérez-Rial S, González-Jiménez J, Pérez-Sánchez JM, Herranz F, Beckmann N, et al. 2008. Magnetic resonance methods and applications in pharma-ceutical research. *J. Pharm Sci*. 97: 3637-65.
- [5] Epstein FH. 2007. MR in mouse models of cardiac disease. *J. NMR Biomed* 20: 238-55.
- [6] Dijkhuizen RM, Nicolay K. 2003. Magnetic resonance imaging in experimental models of brain disorders. *J. Cereb Blood Flow Metab*. 23: 1383-401.
- [7] Anderson SA, Frank JA. 2007. MRI of mouse models of neurological disorders. *J. NMR Biomed*. 20: 200-15.
- [8] Pancholi K. 2012. A review of imaging methods for measuring drug release at nanometre scale: a case for drug delivery systems. *J. Expert Opin Drug Deliv*. 9: 203-18
- [9] Khoo MM, Tyler PA, Saifuddin A, Padhani AR. 2011. Diffusion-weighted imaging (DWI) in musculoskeletal MRI: a critical review. *J. Skeletal Radiol*, 40: 665–681.
- [10] Linn J, Schwarz F, Schichor C, Wiesmann M. 2007. Cranial MRI of small rodents using a clinical MR scanner. *J. Methods* 43: 2–11.
- [11] Inderbitzin D, Stoupis C, Sidler D, Gass M, Candinas D. 2007. Abdominal magnetic resonance imaging in small rodents using a clinical 1,5 T MR scanner. *J. Methods* 43: 46-53.
- [12] Brockmann MS, Kemmling A, Groden C. 2007. Current issues and perspectives in small rodent magnetic resonance imaging using clinical MRI scanners. *J. Methods* 43: 79-87.
- [13] Nolte I, Pham M, Bendszus M. 2007. Experimental nerve imaging at 1,5 T. *J. Methods*. 43: 21-28.
- [14] Beuf O, Jailon F, Saint Jalmes H. 2006. Small animal MRI: signal to noise ratio comparison at 7 and 1,5T with multiple animal acquisition strategies. *J. Magn Resonan Mater Physics*. 19: 202-208.
- [15] Chena F, De Keyzera F, Wanga H, Vandecaveyea V, Landuytc W, Bosmansa H, Hermansa R, Marchala G, Nia Y. 2007. Diffusion weighted imaging in small rodents using clinical MRI scanners. *J. Methods* 43: 12-20.
- [16] Directive 2004/10/EC of the European Parliament and of the Council. 2004. On the harmonization of laws, regulations and administrative provisions relating to the application of the principle of good laboratory practice and the verification of their applications for test on chemical substances. Official Journal of the European Union: L 50/44-L 50/59.
- [17] Food and Drug Administration.1997. Good Laboratory Practice for non-clinical laboratory studies. Title 21 Code of Federal Regulations, Subchapter A, Part 58.
- [18] Cosme K. et al. 2013. Programa para el Uso de Animales de Experimentación del Centro de Ingeniería Genética y Biotecnología. Edición 04.
- [19] Di Pasquale L, Hayes W. 2001. Acute Toxicity and Eye Irritancy. In: Principles and Methods of Toxicology. Taylor and Francis (eds). Philadelphia, USA: 864-867.
- [20] Animal Alternatives, Welfare and Ethics. 1997. Developments in Animal and Veterinary Sciences. L.F.M van Zutphen and M. Balls.
- [21] Gonzalez E, Cabal C. 2011. Criterios Cuantitativos de Selección de la Bobina Receptora de Radiofrecuencia para Estudiar Animales Pequeños en Equipos Clínicos de Resonancia Magnética. V Latin American Congress on Biomedical Engineering CLAIB. 33: 527-530.
- [22] IFMBE Proceedings. Springer Berlin Heidelberg. 2013.